

# EYE FLU CONJUNCTIVITIS CASES UP: CAUSES, SYMPTOMS AND TREATMENTS

Vinayak A. Katekar<sup>1\*</sup>, Sushma V. Ahire<sup>1</sup>, Vaishnavi A. Ghormade<sup>2</sup>, Prafful P. Kothari<sup>3</sup>, Ankita S. Dhopate<sup>4</sup>

<sup>1\*</sup>Department of Quality Assurance Shraddha Institute of Pharmacy, Washim, Maharashtra, India.

<sup>1</sup>Department of Pharmaceutical Chemistry, K.K.Wagh Institute of pharmacy, Nashik, Maharashtra, India.

<sup>2</sup>Department of Pharmaceutics Smt. kusumtai Wankhede Institute of Pharmacy, Katol, Nagpur, Maharashtra, India.

<sup>3</sup>Department of Pharmaceutics Birla Institute of Technology & Science-Pilani, Hyderabad Campus, Jawahar Nagar, Medchal, Hyderabad, Telangana, India.

<sup>4</sup>Department of Quality Assurance S.K.B. College of Pharmacy, Gada Kamptee, Nagpur Maharashtra, India.

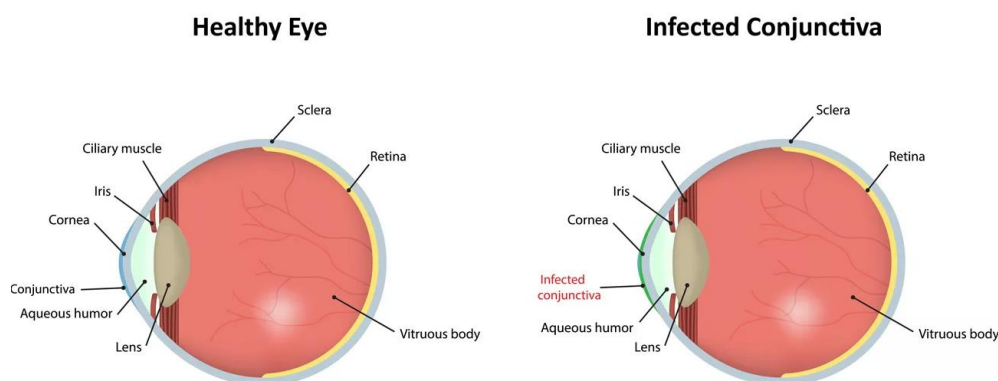
**ABSTRACT:** Eye flu conjunctivitis, also known as pink eyes, is a common and highly contagious eye infection. Viruses, bacteria, allergies, or chemicals can cause excessive redness, itching, and tearing. The main complication of glaucoma is pink eye, which can cause corneal damage that can affect your vision. Acute infectious causes (viral and bacterial) are the most common ocular disorders in primary care. Conjunctivitis infection usually occurs through direct or indirect contact. Direct transmission occurs when an infected person coughs or sneezes. Indirectly, it can spread through common personal items such as towels, makeup, pillows, or contact lenses. Adenoviruses are the most common cause of viral conjunctivitis and are mainly caused by bacteria such as *Staphylococcus aureus* or *Streptococcus pneumoniae*. The most effective prevention is to avoid rubbing the eyes, especially with clean hands. Adenovirus, Haemophilus influenzae, pneumococcal, and Neisseria meningitidis vaccines are also effective.

**KEYWORDS:** Eye Flu, Conjunctivitis, Eye Infection, Pink eye, Adenovirus, Antibiotics

## INTRODUCTION:

Conjunctivitis, also known as pink eyes, is a common and highly contagious eye infection. Viruses, bacteria, or allergies can cause excessive redness, itching, and tearing. Of these, acute infectious causes (viral and bacterial) are the most common ocular disorders in primary care. Although ocular influenza does not pose a major health threat, it is highly contagious and spreads rapidly in crowded areas or through direct contact with infected individuals [1,2]. The main symptom of conjunctivitis is redness or irritation of the eyes [3].

Conjunctivitis Alert With the onset of monsoon, cases of conjunctivitis or 'eye flu' are increasing at an alarming rate in India. In recent days, many areas including Delhi-NCR, Pune, and Lucknow (where the virus accounts for 2,400-2,500 active cases) have witnessed a significant increase in conjunctivitis cases [4,5].

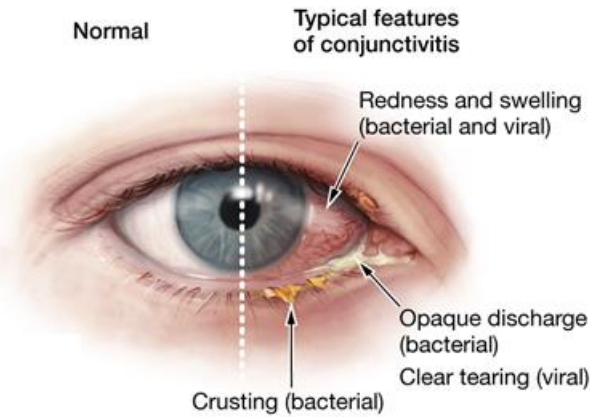


**Figure 1:** Eye Infections (Conjunctivitis)

## How does conjunctivitis spread?

Conjunctivitis infection usually occurs through direct or indirect contact. Direct transmission occurs when an infected person coughs or sneezes. Indirectly, it can spread through common personal items such as towels, makeup, pillows, or contact lenses. Viruses usually spread faster in social settings.

"Conjunctivitis or eye flu has been transmitted through contaminated fingers or contaminated objects. Therefore, if a person suffering from conjunctivitis touches another person, touches the same place, and then touches the eye again, conjunctivitis will be transmitted to a new person "[5,6].



**Figure 2:** Eye with Conjunctivitis (Pink Eye)

### CAUSES OF EYE FLU CONJUNCTIVITIS:

Allergies and irritants such as smoke, dust, pollen, pet dander, and chemicals are common causes of noninfectious conjunctivitis. Also, wearing contact lenses for too long or not cleaning them properly can lead to eye infections. Eye flu or conjunctivitis can be divided into several types based on the cause. These are the types of eye flu you should know about.

#### 1. Viral conjunctivitis:

Viral conjunctivitis is responsible for the majority of infectious conjunctivitis, accounting for 75% of cases [7,8]. Symptoms of viral conjunctivitis include redness, conjunctivitis, oozing, pain, photophobia, and pseudomembranes. There is a significant economic and social impact due to emergency department or general practitioner visits, diagnostic tests, prescription treatments, and time lost from work or school. Prescribing antibiotics for viral conjunctivitis is one of the major costs of the healthcare system. In the UK, the cost of antibiotic treatment in the community for patients with infectious conjunctivitis ranges between 80% and 95% [9,10].

Adenoviruses are the most common cause of viral conjunctivitis. Adenoviruses, members of the *Adenoviridae* family, are immature double-stranded DNA viruses. Common viral infections caused by adenoviruses include urinary tract infections, eye infections, and diarrhea in children. Children are more susceptible to viral infections and adults are more susceptible to bacterial infections. Viral conjunctivitis can be acquired through direct contact with the virus, airborne contamination, and waterborne exposure such as swimming pools [11,12]. Other viral causes include herpes conjunctivitis, acute hemorrhagic conjunctivitis (AHC), and COVID-19 conjunctivitis.

#### 2. Bacterial Conjunctivitis:

It is mainly caused by bacteria such as *Staphylococcus aureus* or *Streptococcus pneumoniae*. This type of conjunctivitis is also contagious and can cause a dark, yellow-green discharge in the corner of the eye in addition to the eye becoming red or pink. Viral and bacterial conjunctivitis are common during the monsoon season due to increased levels of humidity and bacterial and viral contamination [13,14].

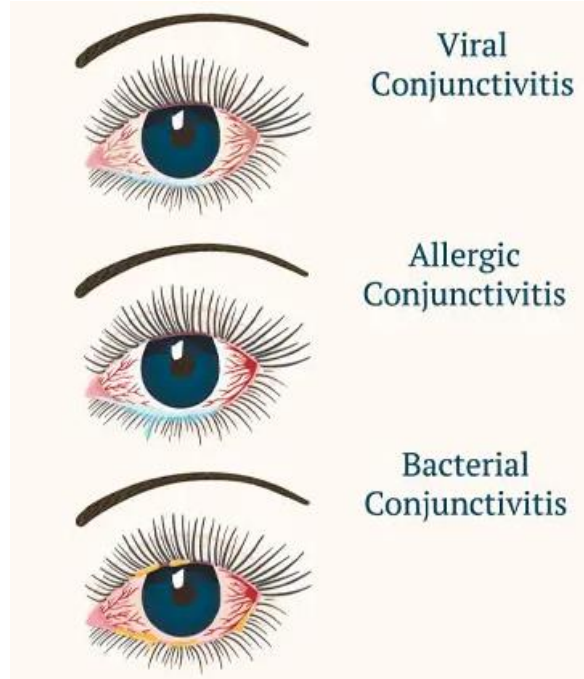
Patients with bacterial conjunctivitis often complain of redness, tearing, and discharge in one or both eyes [15]. The clinician should question the duration of the patient's symptoms because the course of the disease can be divided into hyperacute, acute (less than 3 to 4 weeks), and chronic (more than four weeks) [16]. Associated pain, irritation, visual loss, and photophobia also aid in clinical judgment [15]. A comprehensive history should include exposure to trauma, previous similar episodes, previous treatment, use of contact lenses, immune status, and gender history [15]. Any otitis media should also be interpreted, as children with bacterial conjunctivitis may have concurrent otitis media [17]. It refers to the more common bacterial cause of eye infections [13,15]:

- *Bacillus*.
- *Moraxella spp.*
- *Enterobacteriaceae*.
- *Pseudomonas aeruginosa (P. aeruginosa)*.
- *Streptococcus pneumoniae (S. pneumoniae)*.
- *Staphylococcus aureus (S. aureus)*.

- *Haemophilus influenza.*
- *Neisseria gonorrhoeae.*

### 3. Allergic Conjunctivitis:

This type of eye flu or conjunctivitis is triggered by allergens such as pollen, pet dander, or dust mites. Allergic conjunctivitis affects both eyes and causes excessive irritation, redness, and excessive tearing [18].



**Figure 3:** Types of conjunctivitis

### 4. Germ papillary conjunctivitis (GPC):

Germ papillary conjunctivitis (GPC) is an allergic reaction of the eye. This happens when one or more small round bumps (papilla) develop in the lower part of the eyelid. The lower part of the eyelid is called the superior tarsal conjunctiva. The upper tarsus grows when the eye rubs against a foreign object. The term blindness refers to kidneys or papillae larger than 1 millimeter (mm) [20,21].

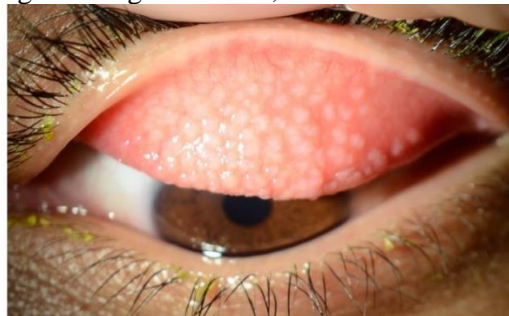There are two types of GPC, primary and secondary. Both are responses to allergens, but they have different causes.

There are two primary types of GPC:

- Vernal kerato-conjunctivitis (VKC)
- Atopic kerato-conjunctivitis (AKC)

The two basic types of GPC have many similarities. It varies based on different underlying causes and the age and manner of onset of symptoms.

Secondary GPC is caused by something irritating the cornea, such as contact lenses or sutures.[20-22].



**Figure 4:** Germ papillary conjunctivitis (GPC)

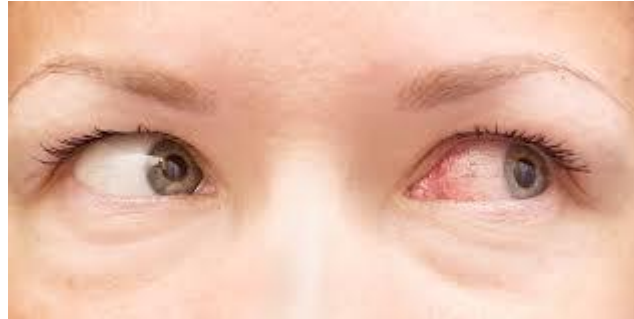### 5. Chemical Conjunctivitis:

Chemical conjunctivitis is weather-related. This is caused by chlorine in pools or harsh chemicals in products. This type of conjunctivitis can cause significant irritation and redness.

Chemical pink eye (conjunctivitis), or toxic pink eye, is caused by smoke, liquids, fumes, or chemicals. Eyes should be washed immediately with running water to remove any toxic chemicals or liquids. Pink eye can be caused by chlorine in pools. Most people do not need treatment [23,24].

Chemical eye injuries account for 11.5%-22.1% of gunshot injuries. About two-thirds of these injuries occur in young adults and children aged 1 to 2 years. Most injuries occur as a result of industrial accidents in the workplace. A small number of injuries occurred at home or in second-degree assault. Alkaline materials are more common in construction materials and cleaning agents and are more common than acid damage [25,26].

Autoimmune disorders and underlying health conditions such as rosacea and Kawasaki disease are associated with chronic cases of conjunctivitis [24].

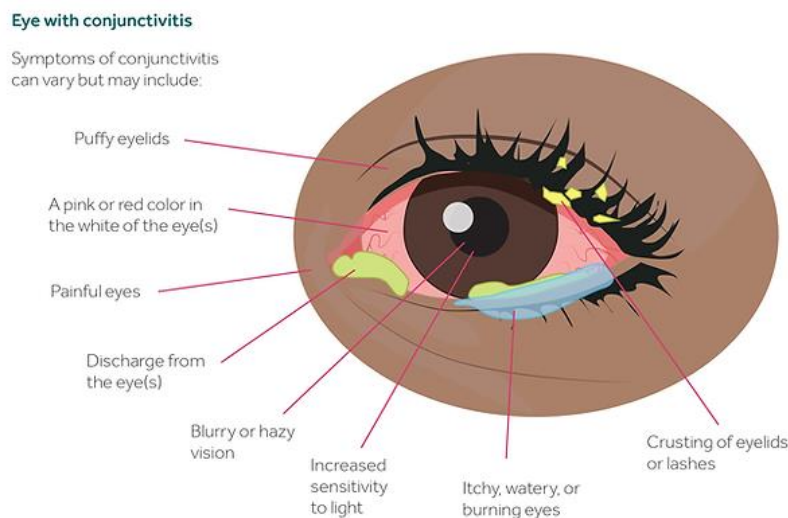


**Figure 5:** Chemical conjunctivitis

### SYMPTOMS OF EYE FLU:

Eye flu symptoms can vary from person to person, but the most common symptoms include pink or red conjunctiva, itching and eye irritation, excessive tearing or watery discharge, thick, yellow, or green discharge, and conjunctivitis, excessive tearing and redness, gritty or gritty feeling in the eyes, eyes become more sensitive to light (photophobia), and the eyelids swell or swell [27].

The eyes may discharge or become watery, and the most prominent symptoms of acute infectious conjunctivitis include mild pruritus, body sensations, and mild photophobia. The most prominent symptoms include general conjunctival infection, usually after sleep, or eyelid crusting and watery or purulent of one or both eyes but no loss of visual acuity [28,29].



**Figure 5:** Symptoms of Conjunctivitis

### DIAGNOSIS OF EYE FLU:

Diagnosing eye flu, also known as conjunctivitis, involves a comprehensive eye exam and a thorough evaluation of the patient's symptoms and medical history. Because ocular influenza can be caused by various factors, including viral or bacterial infections, allergies, or exposure to environmental agents, identifying the cause is important for effective treatment [30,31].

### EYE EXAMINATION:

The first step in diagnosing cataracts is a thorough examination by an eye care professional, such as an optometrist or ophthalmologist. During the examination, the doctor [32,33]:

- **Check the conjunctiva:** Check the conjunctiva for signs of irritation, redness, or swelling.
- **Check visual acuity:** Assess the patient's visual acuity to determine whether there is a change in vision.
- **Inspect the eyelids:** Check the eyelids for crusting, swelling, or discharge.

- **Measure Pupil Reaction:** Assess pupil response to light to ensure they are functioning properly.
- **Evaluate the cornea:** Check the bladder for abnormalities or signs of infection.

### MEDICAL HISTORY:

The eye care professional will also take a detailed medical history, including information about [31-34]:

- **Recent Illness:** Information about any recent illnesses or exposure to infectious individuals may be relevant in identifying viral or bacterial causes.
- **Contact Lens Use:** If the patient wears contact lenses, the eye care professional will inquire about lens hygiene and frequency of use.
- **Symptoms:** The patient will be asked about their symptoms, including the onset, duration, and severity of eye discomfort, redness, itching, or discharge.
- **Allergies:** Allergies to specific substances, such as pollen or pet dander, will be noted to assess the possibility of allergic conjunctivitis.

### PREVENTION AND TREATMENT:

The most effective prevention is to avoid rubbing the eyes, especially with clean hands. Adenovirus, Haemophilus influenzae, pneumococcal, and Neisseria meningitidis vaccines are also effective [35].

Povidone-iodine eye solution has been found to prevent neonatal conjunctivitis. Due to its low cost, it is widely used around the world [36].

#### **Viral conjunctivitis usually gets better in a few days without treatment:**

Broad-spectrum antibiotic eye drops will treat most cases of bacterial conjunctivitis or keratitis, and specific antibiotics are used to treat gonorrhea and chlamydia. Most of these diseases are treatable [37,38].

#### **Most fungal and parasitic infections can be treated with a variety of treatments:**

The exception is Histoplasma, which we know exists, but not in the retina. The only current treatment is laser ablation of the area, which dramatically slows the deterioration of the macula (the center of the retina). This procedure is performed with the hope of preserving existing vision, but in some cases, it can lead to vision loss. It often has to be repeated several times. Although new surgical techniques are being explored, there are still ways to repair the damage already done [37, 39].

Herpes simplex cannot be eliminated from the body, but eye infections can often be treated with topical (surface) or oral (oral) antiviral medications. If there is severe scarring or vision loss from infection, a corneal transplant may be necessary. Serious diseases such as syphilis, syphilis, and toxoplasmosis must be treated for the body before eye problems appear.

Unless you avoid endemic areas (places where this fungus is found, such as river valleys), there is not much you can do to prevent diseases like histoplasmosis. If you are in the area and have a weakened immune system, you should avoid activities associated with histoplasmosis, such as digging, cleaning, or demolishing old buildings, or digging up soil where birds are present. drop crack [40]. You will also find that most eye infections are sexually transmitted or sexually transmitted diseases such as syphilis, chlamydia, gonorrhea, ringworm, herpes simplex, thrush, and hepatitis B. If you have herpes simplex, do not touch your eyes if you have cold sores or active swelling [37-42].

Hand washing is essential to prevent the spread of organisms that can cause infection. To prevent the spread of eye infections, sharing towels, pillowcases, washcloths, and makeup should be avoided [42].

### MANAGEMENT:

Conjunctivitis resolves in 65% of cases in 2-5 days without treatment. Antibiotic prescription is not necessary in most cases [43].

**Table 1: Eye Flu Treatments**

Cause or Type	Eye Flu Treatment
Viral	Antiviral treatments
Bacterial	Antibiotics and ointments for children
Allergic	Antihistamine to stop inflammation Loratadine and diphenhydramine Anti-inflammatory eye drops
Chemical	Rinsing your eyes with saline water or topical steroids are given
Home Remedies	A warm compress or eye drops

#### **Viral conjunctivitis:**

Viral conjunctivitis usually resolves on its own and does not require specific treatment [44]. Antihistamines (eg, diphenhydramine) or mast cell stabilizers (eg, cromolyn) can be used to help with symptoms. Povidone-iodine has been recommended as a treatment, but until 2008 the evidence supporting it was poor [44, 45].

**Bacterial conjunctivitis:**

Bacterial conjunctivitis usually resolves without treatment. Antibiotics may be required only if there is no improvement after 3 days [46]. No serious side effects occurred with or without treatment [47]. Antibiotics can be considered to be used in bacterial conjunctivitis because they are quickly treated [47]. Antibiotics are recommended for people who wear contact lenses, are immune compromised, have chlamydia or gonorrhea, mild pain, or profuse discharge [44]. Gonorrheal or chlamydial infections require oral and topical antibiotics [44].

The choice of antibiotics varies depending on the strain or suspected type of bacteria causing the infection. Fluoroquinolones, sodium sulfacetamide, or trimethoprim/ polymyxin can be used, usually for 7-10 days [48]. Meningococcal conjunctivitis can also be treated with systemic penicillin to penicillin-susceptible.

When studied as a treatment, povidone-iodine ophthalmic solution can be suggested to be effective against bacterial and chlamydial conjunctivitis in areas where topical antibiotics are not available or expensive [49].

**Allergic conjunctivitis:**

For allergic conjunctivitis, cold water head-down constricts capillaries, and artificial tears sometimes help with discomfort in mild cases [50]. In more severe cases, steroids and antihistamines may be prescribed. Persistent allergic conjunctivitis may also require steroid drops [51].

**Table 2:** Some medications for the treatment of Conjunctivitis (Pink Eye)

Conjunctivitis Treatments	Viral Conjunctivitis	Bacterial Conjunctivitis	Allergic Conjunctivitis
Non-steroidal Anti-inflammatory drugs (NSAIDs) (Ex. Ibuprofen)	√	√	
Antihistamine eye drops			√
Steroid eye drops	√		√
Antibiotics (Oral / Eye drops/ointments)		√	
Antiviral Medications	√		
OTC artificial tears (For dryness)	√	√	√
Cool Compress	√	√	√

**Chemical conjunctivitis:**

Chemically induced conjunctivitis is treated by irrigation with lactated Ringer's solution or saline. Chemical injuries, especially burns, are a medical emergency because they can cause severe burns and damage to the inside of the eye. People with chemically induced conjunctivitis should avoid touching their eyes to avoid spreading the chemical [52,53,54].

**CONCLUSION:**

Conjunctivitis is an irritation or inflammation of the conjunctiva, the protective membrane that covers the white part of the eye. Also known as pink eye, it is often caused by a viral or bacterial infection and is highly contagious. It may present with respiratory symptoms such as a cold or a sore throat. Wearing improperly cleaned contact lenses or wearing them yourself can cause bacterial conjunctivitis. The main complication of glaucoma is pink eye, which can cause corneal damage that can affect your vision.

If you are experiencing this problem, you should take appropriate measures and get pink eye treatment. In most cases, antibiotic eye drops will not be necessary. Since conjunctivitis is usually viral, antibiotics will not help. It can even cause harm in the future by reducing the effectiveness or causing drug reactions. In contrast, viruses need time to run their course.

**REFERENCES:**

1. Skevaki CL, Galani IE, Pararas MV, et al. Treatment of viral conjunctivitis with antiviral drugs [J]. *Drugs*, 2011, 71(3):331-347.
2. Rietveld RP, Ter Riet G, Bindels PJ, Schellevis FG, van Weert HC. Do general practitioners adhere to the guideline on infectious conjunctivitis? Results of the Second Dutch National Survey of General Practice. *BMC Fam Pract*. 2007;8:54.
3. Sheikh A, Hurwitz B. Antibiotics versus placebo for acute bacterial conjunctivitis. *Cochrane Database Syst Rev*. 2016;19:CD001211.
4. Mahajan VM. Acute bacterial infections of the eye: Their etiology and treatment. *Br J Ophthalmol*. 1983;67:191-4.
5. <https://www.moneycontrol.com/news/health-and-fitness/rainy-season-monsoon-conjunctivitis-cases-are-at-an-all-time-high-these-days-11027091.html>

6. Belser JA, Lash RR, Garg S, Tumpey TM, Maines TR. The eyes have it: influenza virus infection beyond the respiratory tract. *Lancet Infect Dis.* 2018; (published online Feb 21.)
7. Keen M, Thompson M. Treatment of Acute Conjunctivitis in the United States and Evidence of Antibiotic Overuse: Isolated Issue or a Systematic Problem? *Ophthalmology.* 2017 Aug;124(8):1096-1098.
8. Udeh BL, Schneider JE, Ohsfeldt RL. Cost-effectiveness of a point-of-care test for adenoviral conjunctivitis. *Am J Med Sci.* 2008 Sep;336(3):254-64.
9. Rietveld RP, ter Riet G, Bindels PJ, Schellevis FG, van Weert HC. Do general practitioners adhere to the guideline on infectious conjunctivitis? Results of the Second Dutch National Survey of General Practice. *BMC Fam Pract.* 2007 Sep 16;8:54.
10. Everitt H, Little P. How do GPs diagnose and manage acute infective conjunctivitis? A GP survey. *Fam Pract.* 2002 Dec;19(6):658-60.
11. Li J, Lu X, Jiang B, Du Y, Yang Y, Qian H, Liu B, Lin C, Jia L, Chen L, Wang Q. Adenovirus-associated acute conjunctivitis in Beijing, China, 2011-2013. *BMC Infect Dis.* 2018 Mar 20;18(1):135.
12. Sow AS, Kane H, Ka AM, Hanne FT, Ndiaye JMM, Diagne JP, Nguer M, Sow S, Saheli Y, Sy EHM, De Meideros Quenum ME, Ndoeye Roth PA, Ba EA, Ndiaye PA. [Senegalese experience with acute viral conjunctivitis]. *J Fr Ophtalmol.* 2017 Apr;40(4):297-302.
13. Azari AA, Barney NP. Conjunctivitis: a systematic review of diagnosis and treatment. *JAMA.* 2013 Oct 23;310(16):1721-9.
14. Patel PB, Diaz MC, Bennett JE, Attia MW. Clinical features of bacterial conjunctivitis in children. *Acad Emerg Med.* 2007 Jan;14(1):1-5.
15. Leung AKC, Hon KL, Wong AHC, Wong AS. Bacterial Conjunctivitis in Childhood: Etiology, Clinical Manifestations, Diagnosis, and Management. *Recent Pat Inflamm Allergy Drug Discov.* 2018;12(2):120-127.
16. Beal C, Giordano B. Clinical Evaluation of Red Eyes in Pediatric Patients. *J Pediatr Health Care.* 2016 Sep-Oct;30(5):506-14.
17. Høvdning G. Acute bacterial conjunctivitis. *Acta Ophthalmol.* 2008 Feb;86(1):5-17.
18. Pichichero ME. Bacterial conjunctivitis in children: antibacterial treatment options in an era of increasing drug resistance. *Clin Pediatr (Phila).* 2011 Jan;50(1):7-13.
19. Bielory B and Bielory L. Atopic dermatitis and keratoconjunctivitis. *Immunology and Allergy Clinics of North America.* 2010; 30(3):323-336.
20. Chin T. GPC: Don't call it an allergic reaction. *Rev Optom.* 2006;143(11).
21. Porazinski AD, Donshik PC. Giant Papillary Conjunctivitis in Frequent Replacement Contact Lens Wearers: A Retrospective Study. *CLAO J.* 1999 Jul;25(3):142-147.
22. Anderson D, Kojima R. Topography: A Clinical Pearl. *Optom Manag.* 2007;42(2):35.
23. Colby, K., Chemical injuries of the Cornea. *Focal Points in American Academy of Ophthalmology.* 2010. 28(1): p. 1-14.
24. Barouch F, Colby KA. Evaluation and initial management of patients with ocular and adnexal trauma. In: Miller JW, Azar DT, Blodi B eds. *Albert and Jakobiec's Principles and Practice of Ophthalmology*, 3rd ed. Philadelphia: WB Saunders Elsevier: 2008: 5071-5092.
25. Clare, G., et al., Amniotic membrane transplantation for acute ocular burns. *Cochrane database of systematic reviews*, 2012. 9: p. CD009379.
26. Wagoner, M.D., Chemical injuries of the eye: current concepts in pathophysiology and therapy. *Survey of ophthalmology*, 1997. 41(4): p. 275-313.
27. Smith, V.A., and S.D. Cook, Doxycycline-a role in ocular surface repair. *The British journal of ophthalmology*, 2004. 88(5): p. 619-25.
28. Rihawi, S., M. Frentz, and N.F. Schrage, Emergency treatment of eye burns: which rinsing solution should we choose? *Graefe's Archive for Clinical and experimental ophthalmology - Albrecht von Graefes Archiv fur klinische und experimentelle Ophthalmologie*, 2006. 244(7): p. 845-54.
29. Wirbelauer C. Management of the red eye for the primary care physician. *Am J Med.* 2006;119:302-6.
30. WHO Global Influenza Surveillance Network. Manual for the laboratory diagnosis and virological surveillance of influenza. 2011;59-62.
31. Machała M, Wiatr E, Gawryluk D, Brydak LB. Significance of virological diagnostics for the effective treatment of hospitalized patients infected with influenza virus. *Pneumonol Alergol Pol.* 2006;74(2):166-170.
32. Belser JA, Lash RR, Garg S, Tumpey TM, Maines TR. The eyes have it: influenza virus infection beyond the respiratory tract. *Lancet Infect Dis* 2018; published online Feb 21.
33. Nakagawa H, Noma H, Kotake O, Motohashi R, Yasuda K, Shimura M. Optic neuritis and acute anterior uveitis associated with influenza A infection: a case report. *Int Med Case Rep J.* 2017 Jan 4;10:1-5.
34. Breker DA, Stacey AW, Srinivasan A, Bursztyn LL, Trobe JD, Johnson MW. Vision loss caused by retinal and lateral geniculate nucleus infarction in H1N1 influenza. *J Neuroophthalmol.* 2015 Sep;35(3):265-269.

35. "Protect Yourself From Pink Eye". *Centers for Disease Control and Prevention*. 2 October 2017. Retrieved 18 October 2017.
36. Isenberg SJ. "The ocular application of povidone-iodine". *Community Eye Health*. 2003; 16 (46): 30–1.
37. Bielory BP, O'Brien TP, Bielory L. Management of seasonal allergic conjunctivitis: guide to therapy. *Acta Ophthalmol*. 2012;90:399–407.
38. Marangon FB, Millder D, Alfonso E. Laboratory results in ocular viral diseases: implications in clinical-laboratory correlation. *Arq Bras Oftalmol*. 2007;70:189–94.
39. Udeh BL, Schneider JE, Ohsfeldt RL. Cost-effectiveness of a point-of-care test for adenoviral conjunctivitis. *Am J Med Sci*. 2008;336:254–64.
40. Kaufman HE. Adenovirus advances new diagnostic and therapeutic options. *Curr Opin Ophthalmol*. 2011;22:290–3.
41. Colby K, Pavan-Langston D. Author reply. *Ophthalmology*. 2013;120:e28–9.
42. Hillenkamp J, Reinhard T, Ross RS, et al. Topical treatment of acute adenoviral keratoconjunctivitis with 0.2% cidofovir and 1% cyclosporine: a controlled clinical pilot study. *Arch Ophthalmol*. 2002;109:845–50.
43. Rose P. "Management strategies for acute infective conjunctivitis in primary care: a systematic review". *Expert Opinion on Pharmacotherapy*. Aug 2007; 8 (12): 1903–21.
44. Azari AA, Barney NP. "Conjunctivitis: a systematic review of diagnosis and treatment". *JAMA*. Oct 2013; 310 (16): 1721–9.
45. Bartlett JD, Jaanus SD. *Clinical Ocular Pharmacology*. Elsevier Health Sciences. pp. 454–. ISBN 978-0-7506-7576-5. Archived from the original on 3 December 2016, 2008.
46. Visscher KL, Hutnik CM, Thomas M. "Evidence-based treatment of acute infective conjunctivitis: Breaking the cycle of antibiotic prescribing". *Canadian Family Physician*. Nov 2009; 55 (11): 1071–5.
47. Chen, Yu-Yen; Liu, Su-Hsun; Nurmatov, Ulugbek; van Schayck, Onno Cp; Kuo, Irene C. "Antibiotics versus placebo for acute bacterial conjunctivitis". *The Cochrane Database of Systematic Reviews*. March 2023; 3 (3): CD001211.
48. Yanoff M, Duker JS. *Ophthalmology* (3rd ed.). Edinburgh: Mosby. 2008; pp. 227–236.
49. Isenberg SJ, Apt L, Valenton M, Del Signore M, Cubillan L, Labrador MA, et al. "A controlled trial of povidone-iodine to treat infectious conjunctivitis in children". *American Journal of Ophthalmology*. Nov 2002; 134 (5): 681–8.
50. Alexandrakis, G., R. Haimovici, D. Miller, and E. C. Alfonso. Corneal biopsy in the management of progressive microbial keratitis. *Am. J. Ophthalmol*. 2000; 129:571-576.
51. Patel, Darshak S; Arunakirinathan, Meena; Stuart, Alastair; Angunawela, Romesh. "Allergic eye disease". *British Medical Journal*. 2017; 359: j4706.
52. Alfaro, D. V., S. J. Hudson, M. M. Rafanan, S. T. Moss, and S. D. Levy. The effect of trauma on the ocular penetration of intravenous ciprofloxacin. *Am. J. Ophthalmol*. 2009; 122:678-683.
53. Cekic, O., C. Batman, U. Yasar, N. E. Basci, O. Zilelioglu, and A. Bozkurt. Subretinal fluid levels of topical, oral, and combined administered ciprofloxacin in humans. *Br. J. Ophthalmol*. 2000; 84:1061-1063.
54. Barza, M., A. Kane, and J. Baum. The effects of infection and probenecid on the transport of carbenicillin from the rabbit vitreous humor. *Investig. Ophthalmol. Vis. Sci*. 2013; 22:720-726.